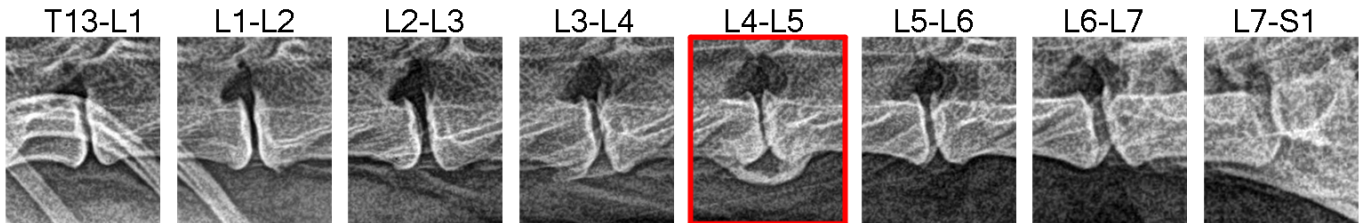




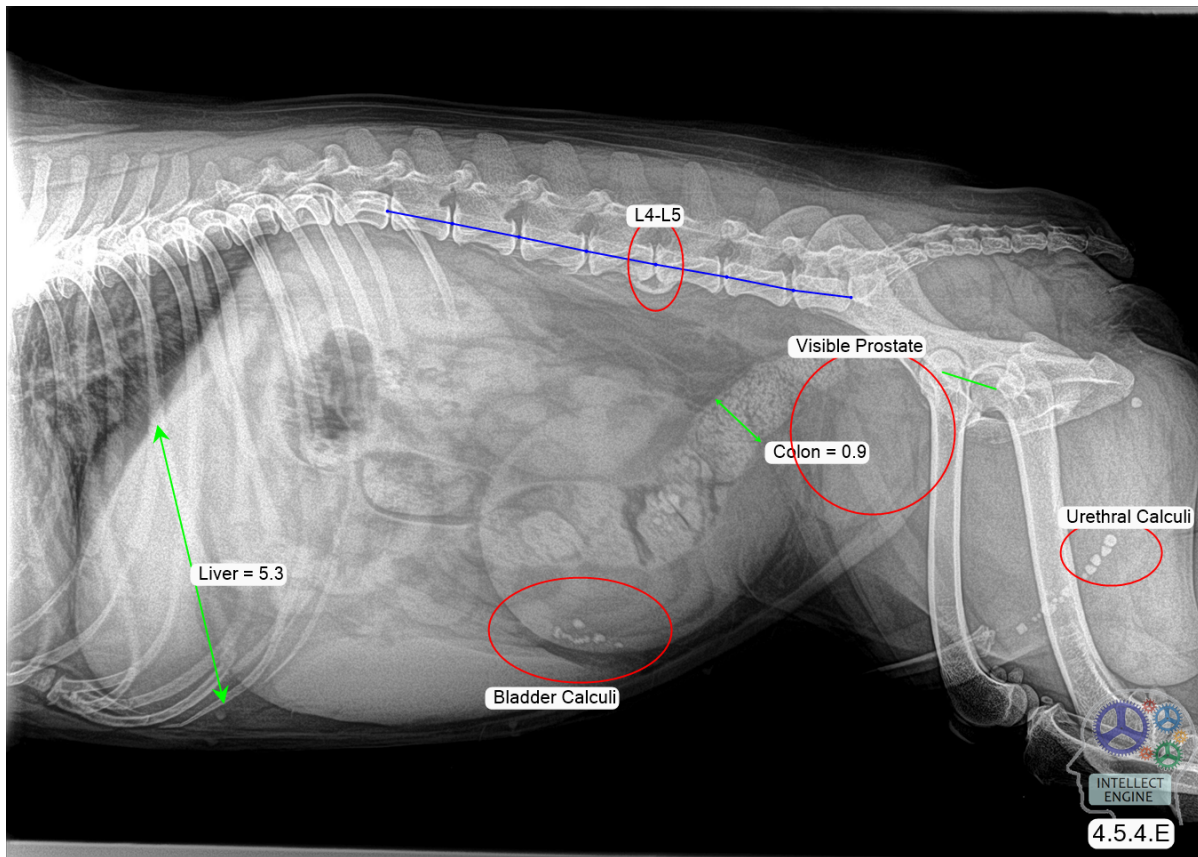
Canine Abdomen

14:57:33

SampleOwner / SampleDog / 27-Mar-2023



Osseous



T13-L1	■	Pregnant	■	Urethral Calculi	■
L1-L2	■	Barium Swallow	■	Visible Prostate	■
L2-L3	■	Mild GD	■	Enlarged Colon	■
L3-L4	■	GD or GDV	■	Rotation	■
L4-L5	■	Enlarged Liver	■	(Good= ■ Bad= ■ N/A= ■ Info= ■)	
L5-L6	■	Micro Liver	■		
L6-L7	■	Renal Mineralization	■		
L7-S1	■	Bladder Calculi	■		

[More Details on this Analysis](#)

References: [J. Choi et al., 2013](#)