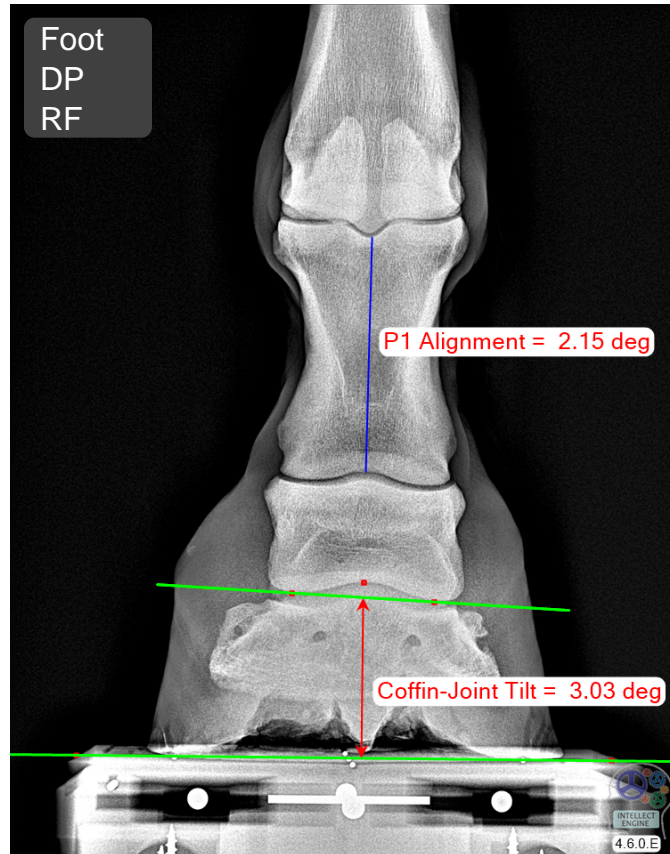




DP Hoof X-Ray

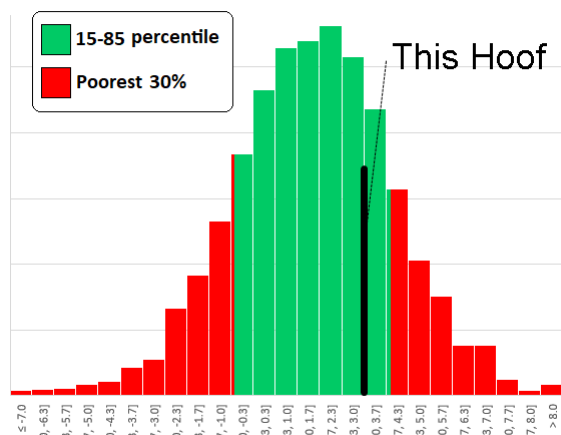
20:32:40

SampleOwner / SampleHorse / 10-Feb-2024



The Coffin-Joint Tilt measurement helps to assess the medial-lateral balance of the hoof. A value of zero occurs when the axis of rotation of the coffin-joint is parallel to ground. A positive value means 'medial heel lower'. The P1-alignment value is not related to the conformation of the hoof, but rather, gives a measure of how well aligned the radiographic apparatus was. This value should be low (say, within +/- 3 degrees) in order to trust the Coffin-Joint Tilt value.

Coffin-Joint Tilt



Data from 5,045 images of mixed breed.

The Coffin-Joint Tilt for this hoof is 3.0 degrees. This value is indicated on the histogram to the left by the vertical black line labelled 'This Hoof'. It is preferred to be in the green zone. The red zone is far away from the norm.

The Coffin-Joint Tilt value is reasonable. It is somewhat below average, but in not in the problem zone.

Link: [Explanation of the Measures](#)